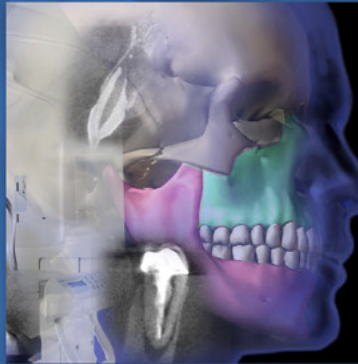

ENDODONTICS



*Colleagues for
Excellence*

Summer 2011

*Cone Beam-Computed Tomography
in Endodontics*



Published for the Dental Professional Community by the
American Association of Endodontists

www.aae.org/colleagues

Radiographic imaging is essential in diagnosis, treatment planning and follow-up in endodontics. The interpretation of an image can be confounded by a number of factors including the regional anatomy as well as superimposition of both the teeth and surrounding dentoalveolar structures. As a result of superimposition, periapical radiographs reveal only limited aspects, a two-dimensional view, of the true three-dimensional anatomy.^{1,2} Additionally, there is often geometric distortion of the anatomical structures being imaged with conventional radiographic methods.³ These problems can be overcome by utilizing small- or limited-volume cone beam-computed tomography imaging techniques, which produce accurate 3-D images of the teeth and surrounding dentoalveolar structures.^{1,2,4}

CBCT is accomplished by using a rotating gantry to which an x-ray source and detector are fixed. A divergent pyramidal- or cone-shaped source of ionizing radiation is directed through the middle of the area of interest onto an area x-ray detector on the opposite side of the patient. The x-ray source and detector rotate around a fixed fulcrum within the region of interest. During the exposure sequence, hundreds of planar projection images are acquired of the field of view (FOV) in an arc of at least 180°. In this single rotation, CBCT provides precise, essentially immediate and accurate 3-D radiographic images. As CBCT exposure incorporates the entire FOV, only one rotational sequence of the gantry is necessary to acquire enough data for image reconstruction. At the present time, CBCT is considered a complementary modality for specific applications rather than a replacement for 2-D imaging modalities.⁴ The Food and Drug Administration approved the first CBCT unit for dental use in the United States in March 2001. Since then, there have been several additional CBCT units approved by the FDA. This newsletter discusses the features, benefits and risks of using CBCT in endodontics.

Field of View (FOV)

The dimensions of the FOV, or scan volume, are primarily dependent on the detector size and shape, beam projection geometry and the ability to collimate the beam. Collimation of the primary x-ray beam limits x-radiation exposure to the region of interest. Field size limitation therefore ensures that an optimal FOV can be selected for each patient based on disease presentation and the region designated to be imaged. In general, the smaller the scan volume, the higher the resolution of the image and the lower the effective radiation dose to the patient. As the earliest sign of a periapical radiographic finding suggestive of pathosis is discontinuity in the lamina dura and widening of the periodontal ligament space, it is desirable that the optimal resolution of any CBCT imaging system used in endodontics not exceed 200µm—the average width of the periodontal ligament space.⁴ The principal limitation of large FOV cone beam imaging is the size of the field irradiated. Unless the smallest voxel (volumetric pixel) size is selected in these larger FOV machines, there will be reduced resolution compared to intraoral radiographs or limited-volume CBCT machines. For most endodontic applications, limited or focused FOV CBCT is preferred over large volume CBCT for the following reasons:

1. Increased resolution to improve the diagnostic accuracy of endodontic-specific tasks such as the visualization of small features including calcified/accessory canals, missed canals, etc.
2. Highest possible resolution.
3. Decreased radiation exposure to the patient.
4. Time savings due to smaller volume to be interpreted.
5. Smaller area of responsibility.
6. Focus on anatomical area of interest.

Radiation Dose Considerations

For a meaningful comparison of radiation risk, radiation exposures are converted to effective dose, measured in Sieverts (Sv). The Sv is a large unit; so in maxillofacial imaging microSieverts [10^{-6} ; µSv] are typically reported. The radiation dose to specific tissues is measured, adjusted for the amount of that tissue in the FOV and weighted based on radiation sensitivity of the tissue. The weighted tissue/organ doses are then summed to assess effective dose. Comparisons can be performed with respect to natural background radiation. The tissues/organs used to calculate the effective dose are specified by the International Commission on Radiological Protection. The organs used to calculate effective dose for imaging of the head include the bone marrow, thyroid, esophagus, skin, bone surface, salivary glands, brain and “remainder” tissues.⁵ Published effective doses for digital radiographs range from 5.5 to 22.0 µSv⁶ (Table 1).

This compares with an average annual effective dose from background radiation in the United States of about 3,000 µSv (3.0mSv). There are a number of factors that will affect the radiation dose produced by a CBCT system: the imaging

parameters used (kVp, mAs); pulsed beam versus continuous beam; amount, type and shape of the beam filtration; the number of basis images dependent partly on the use of 360° or lesser rotations; and limitations on the size of the FOV. Factors such as beam quality and filtration are unique to a specific machine, while other factors, such as FOV, can sometimes be operator controlled. Typically, the smaller the FOV for a given system, the lower the radiation dose applied.^{7,8} Since the effective dose is computed from a weighted summation of doses to various organs, removing some organs from the path of the x-ray beam can reduce the effective dose.

Table 1

Ionizing Radiation Dosages (approximate)		
Activity	Effective Dose in μSv	Dose as Days of Equivalent Background Radiation
1 day background radiation, sea level	7-8	1
1 digital PA radiograph	6	1
4 dental bite-wing radiographs, F-speed film	38	5
FMX; PSP or F-speed film	171	21
Kodak® CBCT focused field, anterior	4.7	0.71
Kodak® CBCT focused field, maxillary posterior	9.8	1.4
Kodak® CBCT focused field, mandibular posterior	38.3	5.47
3D Accuitomo, J. Morita	20	3
NewTom 3G, ImageWorks	68	8
Chest x-ray	170	25
Mammogram	700	106
Medical CT, head	2,000	243
Medical Cat Scan (Spiral CT abdomen)	10,000	1,515
Federal Occupation Safety Limit per Year	50,000	7,575

Ludlow JB et al. *Dosimetry of 3 CBCT devices for oral and maxillofacial radiology. Dentomaxillofac Rad 2006; 35: 219-226.*

White SC, Pharoah MJ. *Oral Radiology: Principles and Interpretation. 2009. Mosby Elsevier, St. Louis, Missouri.*

ALARA Principle

ALARA is the acronym for *As Low As Reasonably Achievable* and is a fundamental principle for diagnostic radiology. Dose minimization can be achieved by:

1. Following appropriate radiograph selection criteria after taking a history from the patient, then clinical evaluation by an appropriate health care professional;
2. The use of properly trained and credentialed personnel to make radiographic exposures upon the prescription of a licensed health care professional;
3. The use of optimal technique factors including beam projection geometry, beam energy, collimation and filtration; and
4. Use of the fastest x-ray detector consistent with obtaining a radiographic image of adequate diagnostic quality.⁹

Clinicians should use CBCT only when the need for imaging cannot be answered adequately by lower dose conventional dental radiography or alternate imaging modalities.

Accuracy of Reproduction: Computed tomography and CBCT images are composed of a huge volume of data consisting of millions of 3-D voxels. CT voxels are anisotropic; the height of the voxel depends on the CT beam slice thickness, which limits the accuracy of reconstructed images. With CBCT data, the voxels are isotropic, meaning they are equal in length, height and depth, which allows for geometrically accurate measurements in any plane.^{10,11} The 3-D accuracy has been confirmed in several studies.^{12,13}

Limitations of CBCT: A significant issue that can affect the image quality and diagnostic accuracy of CBCT images is the scatter and beam hardening artifacts caused by high density adjacent structures, such as enamel, and radiopaque materials such as metal posts, restorations and root filling materials (Figure 1).¹⁴⁻¹⁶ Additional artifacts that may obscure radiographic findings are patient movement during the scan and volume reconstruction.

Patient Selection Criteria: CBCT must not be used routinely for endodontic diagnosis or for screening purposes in the absence of clinical signs and symptoms. The patient's history and clinical examination must justify the use of CBCT by demonstrating that the benefits to the patient outweigh the potential risks.

Interpretation: Clinicians ordering a CBCT are responsible for interpreting the entire image volume just as they are for any other radiographic image. Any radiograph may demonstrate findings that are significant to the health of the patient. There is no informed consent process that allows the clinician to interpret only a specific area of an image volume. Therefore, the clinician can be liable for a missed diagnosis, even if it is outside of his or her area of practice. Any questions by the practitioner regarding image data interpretation should promptly be referred to a specialist in oral and maxillofacial radiology.^{17,18}

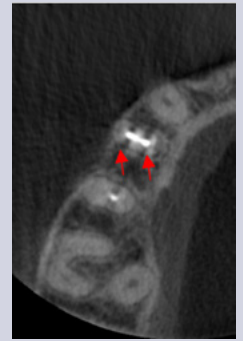

Fig.1. Axial CBCT image of teeth #3-6. Beam hardening artifacts (dark lines) can be seen going mesiodistally from the root filling materials on teeth #4 and 5. These are NOT root fractures.

Advantages of CBCT in Endodontics

Perhaps the most important advantage of CBCT in endodontics is that it demonstrates anatomic features in three dimensions that intraoral and panoramic images cannot. CBCT units reconstruct the projection data to provide interrelational images in three orthogonal planes (axial, sagittal and coronal). In addition, because reconstruction of CBCT data is performed natively using a personal computer, data can be reoriented in its true spatial relationships. Due to the isotropic nature of the constructed volume elements (voxels) constituting the volumetric dataset, image data can be sectioned nonorthogonally. Most software provides for various nonaxial 2-D images in multiplanar reformation. Such MPR modes include oblique, curved planar reformation (providing “simulated” distortion-free panoramic images) and serial transplanar reformation (providing cross-sections), which can be used to highlight specific anatomic regions for diverse diagnostic tasks. Enhancements including zoom magnification, window/level adjustments, and text or arrow annotation can be applied. Cursor-driven measurement algorithms provide the clinician with an interactive capability for real-time dimensional assessment. On-screen measurements are free from distortion and magnification. Because acquisition occurs innately as high-resolution 3-D volumetric data and can be displayed as interactive images, CBCT technology provides the clinician with an unparalleled visualization of the often complex relationships and boundaries between teeth and their associated pathology and anatomic features within the alveolus and jaws, such as the maxillary sinus and mandibular canal and foramen.⁴

In general, the use of CBCT in endodontics should be limited to the assessment and treatment of complex endodontic conditions such as:

- Identification of root canal system anomalies and determination of root curvature.
- Diagnosis of dental periapical pathosis in patients who present with contradictory or nonspecific clinical signs and symptoms, who have poorly localized symptoms associated with an untreated or previously endodontically treated tooth with no evidence of pathosis identified by conventional imaging, and in cases where anatomic superimposition of roots or areas of the maxillofacial skeleton is required to perform task-specific procedures.
- Diagnosis of pathosis of nonendodontic origin in order to determine the extent of the lesion and its effect on surrounding structures.
- Intra- or postoperative assessment of endodontic treatment complications, such as overextended root canal obturation material, separated endodontic instruments, calcified canal identification and localization of perforations.
- Diagnosis and management of dentoalveolar trauma, especially root fractures, luxation and/or displacement of teeth, and alveolar fractures.
- Localization and differentiation of external from internal root resorption or invasive cervical resorption from other conditions, and the determination of appropriate treatment and prognosis.
- Presurgical case planning to determine the exact location of root apex/apices and to evaluate the proximity of adjacent anatomical structures.

Detection of Apical Periodontitis: CBCT enables the detection of radiolucent findings before they are visualized on conventional radiographs (Figures 2a and 2b).¹⁹⁻²⁴ Lesions in the cortical bone can only be detected radiographically when there is perforation of the bone cortex, erosion from the inner surface of the bone cortex, or extensive erosion or defects on the outer surface. It is known that periapical lesions in cancellous bone cannot be detected radiographically.²⁵

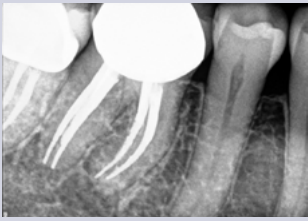

Fig. 2a. Periapical radiograph of tooth #30.

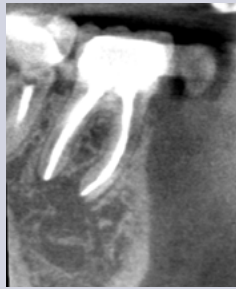

Fig. 2b. Sagittal CBCT slice of tooth #30. Note extensive periapical radiolucency.

CBCT, however, can reveal bone defects of the cancellous bone and cortical bone separately. The prevalence of apical periodontitis was found to be significantly higher when using CBCT, in comparison with periapical radiographs.²⁰ Moreover, the information obtained by CBCT evaluation of periapical repair following root canal treatment was comparable to histological analysis, whereas conventional radiographs underestimated the size of the periapical lesion.²⁴ One study showed that 34% of the radiolucencies detected with CBCT were missed with periapical radiography in maxillary premolars and molars.²² It was concluded that the detection of apical periodontitis was considerably higher with CBCT than with periapical radiography.²⁰ Thus, CBCT was found to be a more sensitive diagnostic method to identify apical periodontitis.

Presurgical Assessment: Three-dimensional imaging allows the anatomical relationship of the root apices to important anatomical structures, such as the inferior dental canal, mental foramen and maxillary sinus, to be clearly identified in any plane the clinician wishes to view.^{17,26-28} It was concluded that CBCT may play an important role in planning for periapical microsurgery on the palatal roots of maxillary first molars.²⁷ The distance between the cortical plate and the palatal root apex could be measured, and the presence or absence of the maxillary sinus between the roots could be assessed. By selecting relevant views and slices of data, the thickness of the cortical plate, the cancellous bone pattern, fenestrations, as well as the inclination of the roots of teeth planned for surgery, can be accurately determined preoperatively.²⁹ CBCT scans from 139 patients were analyzed to evaluate the proximity of the mandibular canal to the root apices of 743 mandibular second premolar and first and second molar teeth.¹⁸ The results revealed that the CBCT scan was an accurate, noninvasive method to evaluate the position of the mandibular canal. The variable position of this structure between patients suggests the need for CBCT to determine the proximity of the nerve bundle before attempting invasive treatment in this area.

Assessment of Tooth Morphology and Complications: Root morphology and bony topography can be visualized in 3-D, as can the number of root canals and whether they converge or diverge from each other. Unidentified and untreated root canals may be identified using axial slices, which may not be readily identifiable with periapical radiographs.^{2,26} The efficacy of CBCT as a modality to accurately identify the presence of second mesiobuccal canals in maxillary first and second molars has been evaluated.²⁸ The CBCT images accurately identified the presence or absence of the MB2 canal in 78.95% of samples. Statistical analysis showed that there was no significant difference in the ability of CBCT scanning to detect the MB2 canal when compared with the gold standard of clinical sectioning. Additionally, CBCT images have clearly demonstrated the presence of untreated or missed canals intraoperatively or in root-filled teeth, as well as complications (*i.e.*, perforations) (Figures 3-5). As such, it appears that the use of CBCT for nonsurgical as well as surgical retreatment can be quite advantageous to the clinician.

Assessment of Tooth Morphology and Complications: Root morphology and bony topography can be visualized in 3-D, as can the number of root canals and whether they converge or diverge from each other. Unidentified and untreated root canals may be identified using axial slices, which may not be readily identifiable with periapical radiographs.^{2,26} The efficacy of CBCT as a modality to accurately identify the presence of second mesiobuccal canals in maxillary first and second molars has been evaluated.²⁸ The CBCT images accurately identified the presence or absence of the MB2 canal in 78.95% of samples. Statistical analysis showed that there was no significant difference in the ability of CBCT scanning to detect the MB2 canal when compared with the gold standard of clinical sectioning. Additionally, CBCT images have clearly demonstrated the presence of untreated or missed canals intraoperatively or in root-filled teeth, as well as complications (*i.e.*, perforations) (Figures 3-5). As such, it appears that the use of CBCT for nonsurgical as well as surgical retreatment can be quite advantageous to the clinician.

Assessment of Tooth Morphology and Complications: Root morphology and bony topography can be visualized in 3-D, as can the number of root canals and whether they converge or diverge from each other. Unidentified and untreated root canals may be identified using axial slices, which may not be readily identifiable with periapical radiographs.^{2,26} The efficacy of CBCT as a modality to accurately identify the presence of second mesiobuccal canals in maxillary first and second molars has been evaluated.²⁸ The CBCT images accurately identified the presence or absence of the MB2 canal in 78.95% of samples. Statistical analysis showed that there was no significant difference in the ability of CBCT scanning to detect the MB2 canal when compared with the gold standard of clinical sectioning. Additionally, CBCT images have clearly demonstrated the presence of untreated or missed canals intraoperatively or in root-filled teeth, as well as complications (*i.e.*, perforations) (Figures 3-5). As such, it appears that the use of CBCT for nonsurgical as well as surgical retreatment can be quite advantageous to the clinician.

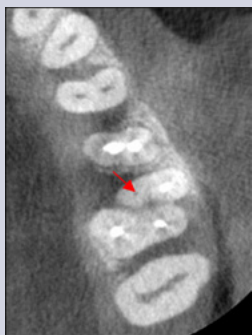

Fig 3. Axial CBCT slice of maxillary left quadrant. Note missed MB2 canal of tooth #14.

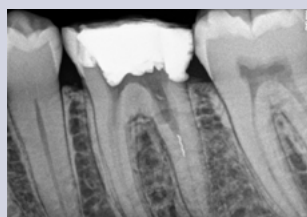

Fig. 4a. Periapical radiograph of tooth #19 with separated instrument in distal root.

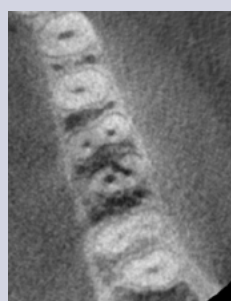

Fig. 4b. Axial CBCT slice of same tooth revealing a strip perforation of distal root at a level coronal to separated instrument.

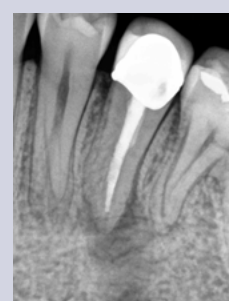

Fig. 5a. Periapical radiograph of tooth #20. There is an associated radiolucency at the apex of this root-filled tooth.

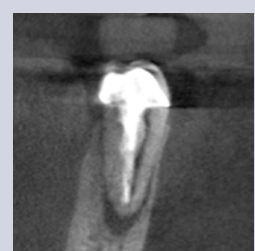

Fig. 5b. Coronal CBCT slice of the same tooth revealing a missed buccal canal and an associated apical radiolucency.

Continued on p. 6

Assessment of Traumatic Injuries and Sequelae: The CBCT provided valuable information that assisted in the determination of the type and severity of dental injuries.³⁰ Horizontal root fractures, resorptive defects (internal, external and invasive cervical) and alveolar fractures are readily observed and differentiated on CBCT images, whereas their diagnoses on periapical radiographs are often quite difficult (Figures 6a and 6b).^{2,31}

Assessment of Vertical Root Fractures: Images obtained on conventional periapical radiographs and 3-D scans for the diagnosis of vertical root fractures have been compared.³² Twenty cases with suspected vertical root fractures were subjected to radiographic imaging. They found that CBCT was significantly better than conventional radiographs in the diagnosis of vertical root fractures. However, fine vertical cracks appear to **not** be revealed on CBCT images at current CBCT resolutions.³³ What may be observed, however, is the resultant vertical bone loss in one or more of the CBCT slices (Figure 7).

Summary

Conventional intraoral radiography provides clinicians with cost-effective, high-resolution imaging that continues to be the front-line method for dental imaging. However, it is clear that there are many specific situations where the 3-D images produced by CBCT facilitates diagnosis and influences treatment. The usefulness of the CBCT cannot be disputed. It is a valuable task-specific imaging modality, producing minimal radiation exposure to the patient and providing maximal information to the clinician.

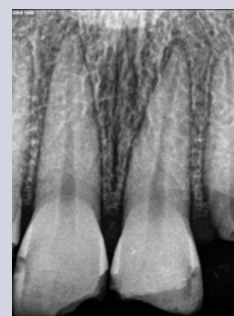


Fig. 6a. Periapical radiograph of teeth #8-9.

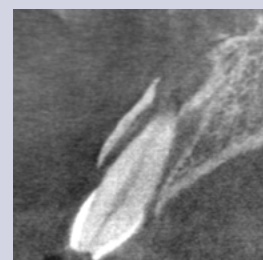

Fig. 6b. CBCT sagittal view of tooth #9 revealing lateral luxation and alveolar fracture.

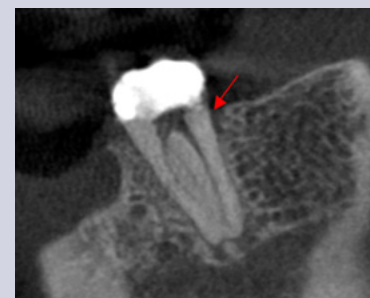

Fig. 7. Sagittal CBCT slice of tooth #18 revealing an isolated osseous radiolucent defect along the mid-distal aspect suggestive of a root fracture.

References

1. Patel S, Dawood A, Pitt Ford T, Whites E. The potential applications of cone beam computed tomography in the management of endodontic problems. *Int Endod J* 2007;40:818-30.
2. Cotton TP, Geisler TM, Holden DT, Schwartz SA, Schindler WG. Endodontic applications of cone beam volumetric tomography. *J Endod* 2007;33:1121-32.
3. Grondahl HG, Huuonen S. Radiographic manifestations of periapical inflammatory lesions. *Endod Topics* 2004;8:55-67.
4. Scarfe WC, Levin MD, Gane D, Farman AG. Use of cone beam computed tomography in endodontics. *Int J Dent* 2009;1-20.
5. Valentin J. The 2007 recommendations of the International Commission on Radiological Protection. Publication 103, *Annals of the ICRP* 2009;37.
6. Ludlow JB, Davies-Ludlow LE, Brooks SL. Dosimetry of two extraoral direct digital imaging devices: NewTom cone beam CT and Orthophos Plus DS panoramic unit. *Dentomaxillofac Rad* 2003;32:229-34.
7. Roberts JA, Drage NA, Davies J, Thomas DW. Effective dose from cone beam CT examinations in dentistry. *Brit J Radiol* 2009;82:35-40.
8. Ludlow JB, Davies-Ludlow LE, Brooks SL, Howeron WR. Dosimetry of 3 CBCT devices for oral and maxillofacial radiology: CB Mercuray, NewTom, 3G and i-CAT. *Dentomaxillofac Rad* 2006;35:219-26.
9. Farman AG. ALARA still applies. *Oral Surg Oral Med Oral Path Oral Radiol Endod* 2005;100:395-7.
10. Scarfe WC, Farman AG, Sukovic P. Clinical applications of cone beam computed tomography in dental practice. *J Canadian Dent Assoc* 2006;72:75-80.
11. Scarfe WC, Farman AG. What is cone beam CT and how does it work? *Dent Clin N Amer* 2008;52:707-30.
12. Ludlow JB, Lester WS, See M, Bailey LJ, Hershey HG. Accuracy of measurements of mandibular anatomy in cone beam computed tomography images. *Oral Surg Oral Med Oral Path Oral Radiol Endod* 2007;103:534-42.
13. Strateman SA, Huang JC, Maki K, Miller AJ, Hatcher DC. Comparison of cone beam computed tomography imaging with physical measures. *Dentomaxillofac Rad* 2008;37:80-93.

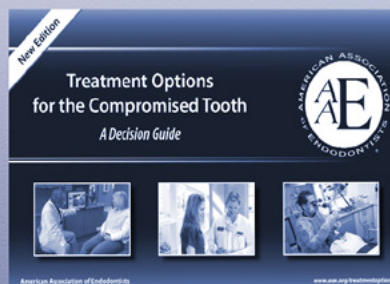
14. Mora MA, Mol A, Tyndall DA, Rivera E. In vitro assessment of local tomography for the detection of longitudinal tooth fractures. *Oral Surg Oral Med Oral Path Oral Radiol Endod* 2007;103:825-9.
15. Katsumata A, Hirukawa A, Noujeim M, Okumura S, Naitoh M, Fujishita M, Arijji E, Langlais RP. Image artifact in dental cone beam CT. *Oral Surg Oral Med Oral Path Oral Radiol Endod* 2006;101:652-7.
16. Barrett JF, Keat N. Artifacts in CT: recognition and avoidance. *Radiographic* 2004;24:1679-91.
17. Use of Cone Beam-Computed Tomography in Endodontics. Joint Position Statement of the American Association of Endodontists and the American Academy of Oral and Maxillofacial Radiology 2010.
18. Kovisto T, Ahmad M, Bowles W. Proximity of the mandibular canal to the tooth apex. *J Endod* 2011;37:311-5.
19. Lofthag-Hansen S, Huumonen S, Grondahl K, Grondahl HG. Limited cone beam CT and intraoral radiography for the diagnosis of periapical pathology. *Oral Surg Oral Med Oral Path Oral Radiol Endod* 2007;103:114-9.
20. Estrela C, Bueno MR, Leles CR, Azevedo B, Azevedo JR. Accuracy of cone beam computed tomography and panoramic radiography for the detection of apical periodontitis. *J Endod* 2008;34:273-9.
21. Patel S, Mannocci F, Wilson R, Dawood A, Pitt Ford T. Detection of periapical defects in human jaws using cone beam computed tomography and intraoral radiography. *Int Endod J* 2009;42:507-15.
22. Low K, Dula K, Burgin W, von Arx T. Comparison of periapical radiography and limited cone beam computed tomography in posterior maxillary teeth referred for apical surgery. *J Endod* 2008;34:557-62.
23. Yoshioka T, Kikuchi I, Adorno CG, Suda H. Periapical bone defects of root filled teeth with persistent lesions evaluated by cone beam computed tomography. *Int Endod J* 2011;44:245-52.
24. Paula-Silva FG, Wu MK, Leonardo MR, da Silva LA, Wesselink PR. Accuracy of periapical radiography and cone beam computed tomography scan in diagnosing apical periodontitis using histopathological findings as a gold standard. *J Endod* 2009;35:1009-12.
25. Bender IB, Seltzer S. Roentgenographic and direct observation of experimental lesions in bone: I. *J Endod* 2003;29:702-6.
26. Patel S. New dimensions in endodontic imaging: Part 2. Cone beam computed tomography. *Int Endod J* 2009;42:463-75.
27. Rigolone M, Pasqualkini D, Bianchi L, Berutti E, Bianchi SD. Vestibular surgical access to the palatine root of the superior first molar: low-dose cone beam CT analysis of the pathway and its anatomic variations. *J Endod* 2003;29:773-5.
28. Blattner TC, George N, Lee CC, Kumar V, Yelton CD. Efficacy of cone beam computed tomography as a modality to accurately identify the presence of second mesiobuccal canals in maxillary first and second molars: A pilot study. *J Endod* 2010;36:867-70.
29. Nakata K, Naitoh M, Izumi M, Inamoto K, Arijji E, Nakamura H. Effectiveness of dental computed tomography in diagnostic imaging of periradicular lesion of each root of a multi-rooted tooth: case report. *J Endod* 2006;32:583-7.
30. Cohenca N, Simon JH, Roges R, Morag Y, Malfaz JM. Clinical indications for digital imaging in dento-alveolar trauma. Part 1: traumatic injuries. *Dent Traumatol* 2007;23:95-104.
31. Bhuva B, Barnes JJ, Patel S. The use of limited cone beam computed tomography in the diagnosis and management of a case of perforating internal root resorption. *Int Endod J* 2011; in press.
32. Bernardes RA, de Moraes IG, Húngaro Duarte MA, Azevedo BC, de Azevedo JR, Bramante CM. Use of cone beam volumetric tomography in the diagnosis of root fractures. *Oral Surg Oral Med Oral Pathol Oral Radiol Endod* 2009;108:270-7.
33. Khayat B, Michonneau JC. Cone beam in endodontics. *Endod Practice* 2009;44-8.

Saving the Natural Tooth *Just Got Easier*

The AAE's *Treatment Options for the Compromised Tooth Guide* helps you evaluate a variety of conditions using:

- case examples with radiographs and clinical photographs;
- clinical considerations; and
- guidance for successful outcomes based on prognosis.

Download your free copies today at
www.aae.org/treatmentoptions



Also available—*Treatment Options for the Diseased Tooth* patient brochure!

- Describes endodontic treatment options in easy-to-understand language
- Explains the benefits of implants when a tooth must be extracted

The AAE wishes to thank Dr. Frederic Barnett for authoring this issue of the newsletter, as well as the following article reviewers: Drs. James A. Abbott, Gary R. Hartwell, William T. Johnson and James F. Wolcott.

AAE Colleagues Online

Exclusive Bonus Materials

This issue of the *ENDODONTICS: Colleagues for Excellence* newsletter is available online at www.aae.org/colleagues with the following *exclusive bonus materials*:

- Use of Cone Beam-Computed Tomography in Endodontics. Joint Position Statement of the American Association of Endodontists and the American Academy of Oral and Maxillofacial Radiology 2010.
- Full Text Article: Michetti J, Maret D, Mallet J, Diemer F. Validation of Cone Beam-Computed Tomography as a Tool to Explore Root Canal Anatomy. *J Endod* 2010;36:1187-90.
- Full Text Article: Tyndall D, Rathore S. Cone-Beam CT Diagnostic Applications: Caries, Periodontal Bone Assessment, and Endodontic Applications. *Dent Clin N Am* 2008;52:825-41.

All back issues of this newsletter are also available for your ongoing reference online.

Earn CE With *Colleagues*

With an annual subscription to the AAE Live Learning Center you can earn CE credit for the *ENDODONTICS: Colleagues for Excellence* newsletter series. Visit the AAE Live Learning Center at www.aae.org/livelearningcenter for more information.



The information in this newsletter is designed to aid dentists. Practitioners must use their best professional judgment, taking into account the needs of each individual patient when making diagnosis/treatment plans. The AAE neither expressly nor implicitly warrants against any negative results associated with the application of this information. If you would like more information, consult your endodontic colleague or contact the AAE.

American Association of Endodontists
211 E. Chicago Ave., Suite 1100
Chicago, IL 60611-2691
info@aae.org • www.aae.org

 www.facebook.com/endodontists

 www.youtube.com/rootcanalspecialists

Did you enjoy this issue of *ENDODONTICS*? Are there topics you would like *ENDODONTICS* to cover in the future? We want to hear from you! Send your comments and questions to the American Association of Endodontists at the address at left.